

PATIENT

Suzy Q Bradshaw

SPECIES

Canine

BREED

Pomeranian

SEX

FS

AGE

10 y

WEIGHT

9.2 lb

INTERPRETED BY

Keith Blass, DVM, MS,
DACVIM (Cardiology)

IMAGING PERFORMED BY

Jessica Bailes

HOSPITAL NAME

All Creatures Great &
Small Corvallis

REFERRING VET

Dr. Sadahiro

INVOICE

DATE

4/30/26

PRESENTING CLINICAL SIGNS

Grade IV/VI murmur. Started on pimobendan 1.2 mg BID years ago after radiographs showed cardiomegaly. Seen six weeks ago for a worsening cough – responsive to prednisone and hydrocodone. Radiographs taken last month showed left atrial enlargement and mild mainstem bronchial compression.

ECHOCARDIOGRAPHIC FINDINGS

2D, M-mode, and Doppler study.

There is moderate left atrial dilation. The mitral valve leaflets are thickened and exhibit systolic prolapse. A moderate jet of eccentric mitral regurgitation is present. There is moderate left ventricular dilation. Left ventricular systolic function is hyperdynamic. The aorta and aortic valve are normal. Right atrial and right ventricular dimensions are normal. The tricuspid valve appears normal, though trace tricuspid regurgitation is present. The pulmonary artery and pulmonic valve appear normal, though trace pulmonic insufficiency is present. No shunting lesions are visualized. No pericardial or pleural effusion is seen.

LA – 29.9 mm
LVIDd – 30.3 mm
LVIDs – 11.0 mm
FS – 63.7%
RA – 15.1 mm
LVOT – 1.48 m/s
RVOT – 1.00 m/s

ASSESSMENT/RECOMMENDATIONS

Degenerative mitral valve disease – stage B2

This examination demonstrates regurgitation of blood across Suzy Q's mitral valve resulting from degenerative valve disease. Secondary to her regurgitation, Suzy Q has moderate dilation of both her left atrium and left ventricle, though her left ventricular systolic function is well-preserved. Given this, it's possible that mainstem bronchial compression could be contributing to Suzy Q's recently worsening cough, and she is at moderately increased risk for the development of other clinical signs, such as exercise intolerance, syncope, and labored breathing.

Continued use of pimobendan is warranted based on this exam. While Suzy Q's cough is currently controlled with prednisone and hydrocodone, the addition of furosemide (5 mg BID) would be warranted if her cough worsens again.

A recheck echocardiogram is recommended in 6-9 months. Recheck radiographs are recommended if Suzy Q experiences difficulty breathing.



PATIENT

Suzy Q Bradshaw

SPECIES

Canine

BREED

Pomeranian

SEX

FS

AGE

10 y

WEIGHT

9.2 lb

INTERPRETED BY

Keith Blass, DVM, MS,
DACVIM (Cardiology)

IMAGING PERFORMED BY

Jessica Bailes

HOSPITAL NAME

All Creatures Great &
Small Corvallis

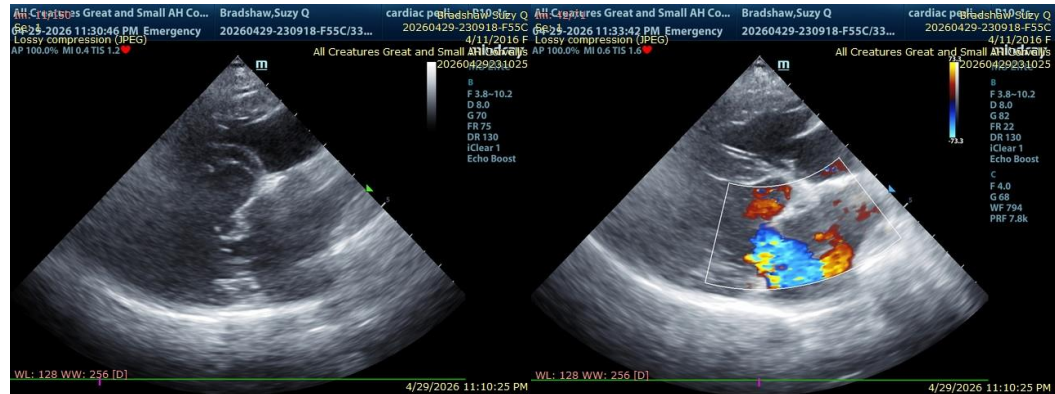
REFERRING VET

Dr. Sadahiro

INVOICE

DATE

4/30/26



The information and recommendations provided are based on the images presented by the referring veterinarian/sonographer. No evaluation can be communicated regarding pathology that was not visible in the image/video clips provided.

Thank you for this referral. If the clinical or image interpretation does not parallel your findings or if I can be of any further assistance please contact me.

Keith Blass, DVM, MS, DACVIM (Cardiology)

info@SonoPath.com